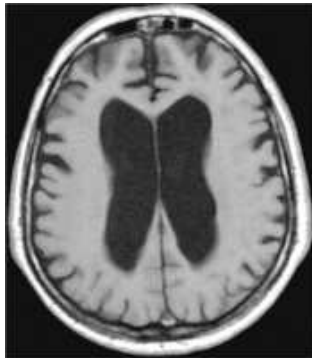

NPH (Normal pressure hydrocephalus)



Clinical picture

A hydrocephalus is a pathological enlargement of the ventricles of the brain as a result of an increased volume of cerebrospinal fluid (CSF) in the brain. It can have various causes.

Idiopathic normal pressure hydrocephalus (INPH) was first described in 1965 by Hakim and Adams (Adams 1965). It is estimated that up to 6 % of all cases of dementia correlate with INPH (Savolainen, Paljarvi et al. 1999). Whereas the idiopathic form of NPH is a disease of older persons (> 60 years), secondary NPH occurs as a sequel of subarachnoid or intraventricular hemorrhage, meningitis, craniocerebral trauma or chronic stenosis of the cerebral aqueduct. The pathophysiology of INPH has not yet been clarified (see below).

It is difficult to establish the diagnosis of NPH in older individuals since similar symptoms are produced by a number of other conditions, e.g. general mental deterioration (dementia), Alzheimer's disease, impaired cerebral circulation and Parkinson's disease.

Clinical symptoms

The classic diagnostic criteria for this disease are:

1. the Hakim triad of gait instability, dementia and urinary incontinence
2. visualization of a communicating hydrocephalus on CT or MRI
3. normal CSF pressure recorded by intermittent lumbar measurement
4. improvement of the patient's symptomatology by placement of a ventriculoperitoneal shunt.

The clinical triad of gait instability, dementia and urinary incontinence (Hakim triad) is characteristic, but not pathognomonic, for NPH. Gait instability is generally the first symptom and is characterized by a wide-based, short-stepped and distinctly slowed gait. The dementia manifests itself primarily as a deterioration of memory accompanied by bradyphrenia and bradykinesia. According to various estimates, up to 6% of all cases of dementia are caused by NPH. The incontinence is marked by involuntary passage of urine without a prior urge to urinate.

Diagnostic procedures

At present there is no laboratory test that is pathognomonic for the presence of NPH. In the absence of such a test, the diagnosis is made on the basis of the clinical and radiological criteria described above and the Tap Test.

Lumbar puncture/Tap Test

In patients with NPH the basal intermittently measured CSF pressure is in the normal range (Adams 1965). A positive Tap Test result is an important criterion for a diagnosis of NPH. In this test approx. 20-30 ml of CSF are drained via lumbar puncture. The test result is deemed positive if the patient's cognitive performance and gait improve after lumbar puncture.

Continuous CSF pressure measurement

During continuous CSF pressure measurement some patients with a normal opening pressure recorded during lumbar measurement display intermittent pressure peaks of > 270 mm of water or repeatedly occurring B waves (Hakim and Adams 1965). In unclear cases we perform epidural pressure measurement over a 48-hour period to achieve greater diagnostic clarity.

Imaging methods

The presence of a communicating hydrocephalus is a prerequisite for a diagnosis of normal pressure hydrocephalus. The principal result of the imaging studies is that the dilatation of the fluid spaces is limited to the ventricles; there is no generalized cerebral atrophy. Specific radiological signs of NPH are:

- decreased periventricular density on CT or MRI (transependymal edema)
- flattening of the sulci in the region of the convexity
- rounding of the anterior horns

Treatment

Placement of a ventriculoperitoneal shunt is the treatment of choice. During this procedure cerebrospinal fluid is drained from a cerebral ventricle via a tubing system connected to a shunt valve that has been placed under the skin in the abdominal cavity. The cerebrospinal fluid is then reabsorbed in the abdominal cavity. At the Sana Kliniken Duisburg the abdominal component of the shunt system is installed laparoscopically, i.e. via an endoscope. This technique simplifies placement of the drainage tube in the abdominal cavity and results in greater safety for the patient.

The valve can be adjusted from the outside by a magnet to regulate the volume of cerebrospinal fluid draining from the cerebral ventricle. The operation is carried out under general anesthesia and takes approx. 45 minutes. Three small skin incisions are made (on the head, behind the ear and in or next to the umbilicus) for the placement of the shunt system.

Acute complications are extremely rare; they include cerebral hemorrhage and injury to the abdominal vessels. Over the long term excessive drainage of CSF may occur in rare cases. Other possible complications are infections of the shunt system; in this case the system must be removed surgically. However, this procedure is usually tolerated very well.

This procedure necessitates a hospital stay of about one week. The patient should come in again for a follow-up examination one month after the procedure and annually after that.

Results

A total of 40-60% of the patients experience a distinct improvement of their symptomatology after shunting. This applies especially to their gait and urinary continence (Savolainen, Paljarvi et al. 1999).

Hypotheses on the molecular pathophysiology of idiopathic normal pressure hydrocephalus (INPH)

The molecular causes of INPH are not known. Fibrosed arachnoid villi are found in about 50% of cases (Bech, Waldemar et al. 1999). Part of the pathophysiology can thus be explained by blockage of CSF absorption structures. Patients with pronounced fibrosis of the arachnoid villi apparently display more clinical improvement after shunting than patients with NPH due to other causes. Moreover, there is a high rate of comorbidity between INPH and Alzheimer's disease (Bech, Waldemar et al. 1999; Savolainen, Paljarvi et al. 1999; Golomb, Wisoff et al. 2000). It is interesting to note in this context that the simultaneous occurrence of Alzheimer's and INPH does not significantly affect the clinical prognosis (Bech, Waldemar et al. 1999; Golomb, Wisoff et al. 2000). To this extent, NPH-associated dementia represents a form of dementia that can be treated successfully.

In some patients with hydrocephalus, however, the drainage of cerebrospinal fluid within the ventricle system is impaired. There may be stenosis of the sylvian aqueduct connecting the third and fourth ventricles, for example.

It is interesting to note that 20% of juvenile patients with hydrocephalus belong to this group. These patients can undergo endoscopic surgery: here a hole – called a ventriculostomy – is made in the floor of the third ventricle via an endoscope that has been introduced through a frontal burr hole. The cerebrospinal fluid is thus drained via an alternative route circumventing the aqueduct. Although this method is not without risks, it offers an option for treating hydrocephalus without shunting, i.e. without the implantation of a foreign body.

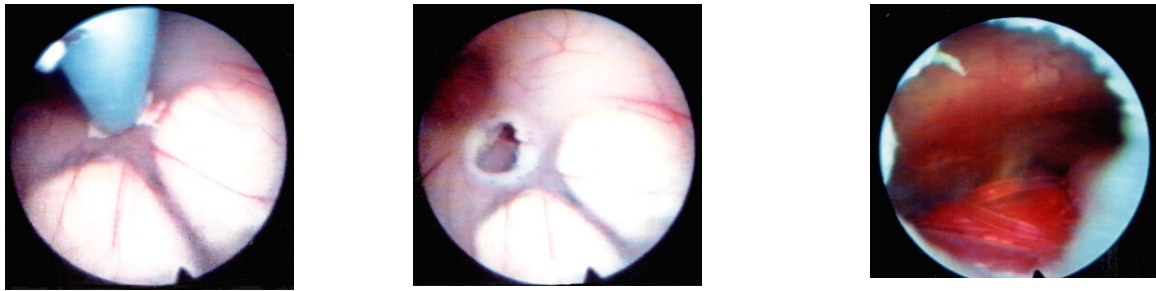


Fig.: Endoscopic ventriculostomy on the floor of the third ventricle.

- Adams, R. D., Fisher, C.M., Hakim, S., Ojeman, R.G., Sweet, W.H. (1965). "Symptomatic occult hydrocephalus with "normal" pressure. A treatable syndrome." New England Journal of Medicine 273: 307-327.
- Bech, R. A., G. Waldemar, et al. (1999). "Shunting effects in patients with idiopathic normal pressure hydrocephalus; correlation with cerebral and leptomeningeal biopsy findings." Acta Neurochir (Wien) 141(6): 633-9.
- Black, P. M. (1980). "Idiopathic normal-pressure hydrocephalus. Results of shunting in 62 patients." J Neurosurg 52(3): 371-7.
- Finckh, U., J. Schroder, et al. (2000). "Spectrum and detection rate of L1CAM mutations in isolated and familial cases with clinically suspected L1-disease." Am J Med Genet 92(1): 40-6.
- Golomb, J., J. Wisoff, et al. (2000). "Alzheimer's disease comorbidity in normal pressure hydrocephalus: prevalence and shunt response." J Neurol Neurosurg Psychiatry 68(6): 778-81.
- Graham DI, L. P. (1997). Greenfield's Neuropathology. London, Arnold.
- Hakim, S. and R. D. Adams (1965). "The special clinical problem of symptomatic hydrocephalus with normal cerebrospinal fluid pressure. Observations on cerebrospinal fluid hydrodynamics." J Neurol Sci 2(4): 307-27.
- Hong, H. K., J. H. Lass, et al. (1999). "Pleiotropic skeletal and ocular phenotypes of the mouse mutation congenital hydrocephalus (ch/Mf1) arise from a winged helix/forkhead transcription factor gene." Hum Mol Genet 8(4): 625-37.
- Petersen, R. C., B. Mokri, et al. (1985). "Surgical treatment of idiopathic hydrocephalus in elderly patients." Neurology 35(3): 307-11.
- Savolainen, S., L. Paljarvi, et al. (1999). "Prevalence of Alzheimer's disease in patients investigated for presumed normal pressure hydrocephalus: a clinical and neuropathological study." Acta Neurochir (Wien) 141(8): 849-53.